

Fulminant Necrotising Fasciitis Caused by *Vibrio Parahaemolyticus*

T K Lim, A E L Stebbings

ABSTRACT

We report a patient with septicaemia and fulminant necrotising fasciitis caused by *Vibrio parahaemolyticus*. This organism is strongly associated with seawater exposure and seafood ingestion. The patient recovered due to expedient management, prompt recognition of the organism, appropriate antimicrobial cover and surgical debridement. The lesson to be learned is that this organism should be clinically suspected and recognised from its typical history of injury and fulminant clinical progress as a delay in diagnosis and treatment may result in an increased risk of mortality.

Keywords: necrotising fasciitis, marine organisms, liver disease, treatment

INTRODUCTION

Necrotising fasciitis may be caused by a variety of organisms, commonly the *Streptococcus*, *Staphylococcus* and some gram negative organisms⁽¹⁾. The progression of the disease may be gradual or have a fulminant course. We report a case of necrotising fasciitis caused by *Vibrio parahaemolyticus* which had a fulminant course. The patient recovered due to a high clinical suspicion of the organism from the outset of the illness and expedient management.

CASE REPORT

A 65-year-old Chinese man with chronic obstructive pulmonary disease was admitted to hospital with a cut on his right arm. The evening prior to admission, the patient was cleaning uncooked crabs. This caused a two-centimetre superficial cut on his right forearm. The following morning, the patient complained of fever, chills and pain of his right forearm, and sought medical attention at a nearby hospital.

On examination, the patient was thin and frail, but alert. Vital signs were as follows: a fever of 38.1°C, pulse 100 beats per minute, blood pressure 120/70 mmHg. The right forearm had a two centimetre laceration which was discharging pus, surrounded by an area of erythema from the wrist to the elbow. Investigations were as follows: Haemoglobin was 13.5 g/dL, white cell count was $8.9 \times 10^9/L$ (polymorphs 90%, lymphocytes 6%, monocytes 2%), and platelets were $235 \times 10^9/L$.

Urea and electrolytes were normal. A diagnosis of cellulitis was made and the patient was treated with tetanus toxoid, intravenous ceftriaxone and cloxacillin. During the night, the patient developed hypotension; blood pressure was 80/60 mmHg, pulse rate was 96 beats per minute and was resuscitated with intravenous fluids. The following morning, the erythema and swelling of the right arm extended from the axilla to the wrist with tenderness and fluctuation of the soft tissue (Figs 1 and 2); blood pressure was 100/80 mmHg and pulse rate was 92 beats per minute. A diagnosis of acute necrotising fasciitis was made. Gram stain of the blood cultures identified gram negative oxidase positive rods. A repeat full blood count showed haemoglobin 11.1 g/dL, white cell count $15 \times 10^9/L$ (polymorphs 93.8%, lymphocytes 3%, monocytes 2%), platelets $252 \times 10^9/L$ with fragmentation and left shift seen on the peripheral blood film. His prothrombin time was 16.3 seconds, partial and thromboplastin time was 64.2 seconds, and

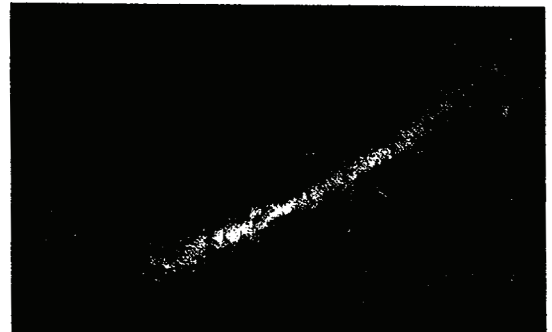


Fig 1 – Right arm of the patient showing extensive erythema and swelling.

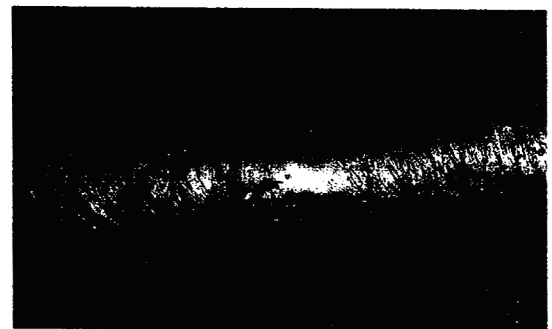


Fig 2 – Close-up view of the right arm shows the laceration caused by a cut from the uncooked crab.

Department of Medicine
National University Hospital
5 Lower Kent Ridge Road
Singapore 119074

A E L Stebbings, MRCP (UK)
Registrar

T K Lim, MMed
Associate Professor

Correspondence to:
A/Prof T K Lim

thrombin clotting time was 16.8 seconds. Arterial blood gas analysis on 2 litres of oxygen by nasal cannulae showed pH 7.36, PO₂ 71.3 mmHg, pCO₂ 55.7 mmHg, standard bicarbonate 19.1 mmol/L, and oxygen saturation 94%. The patient was managed with aggressive intravenous fluid replacement which resulted in the improvement of his blood pressure to 170/100 mmHg; a change in antibiotic therapy to ceftazidime and doxycycline, and expedient surgical debridement of the subcutaneous tissue in view of the hypotension, clinical suspicion of *Vibrio vulnificus* as the aetiological agent and rapidity of the disease progression. During the operation, the surgeon noted extensive swelling of the skin and subcutaneous fascia of the right arm. Blood cultures subsequently isolated *Vibrio parahaemolyticus* which is sensitive to ampicillin, piperacillin, augmentin, cephalexin, cefuroxime, ceftazidime, ceftriaxone, gentamicin, co-trimoxazole, ciprofloxacin, imipenem, cefoperazone and cefotaxime. Post-operatively, the patient was monitored in the intensive care unit for two days for ventilatory and inotropic support. The wounds gradually healed and the patient made an uneventful recovery after two weeks of antibiotics.

DISCUSSION

This patient had necrotising fasciitis caused by an unusual organism known to be highly virulent and associated with a mortality of 22%⁽²⁾. The organism was suspected as a result of his injury from uncooked crabs, gram stain of the blood cultures and the rapidity of the disease progression. Aggressive management with intravenous fluids, appropriate antibiotics and expedient surgical debridement was carried out resulting in full recovery of the patient.

Vibrio parahaemolyticus causes a range of clinical syndromes: gastroenteritis, primary septicemia and wound infections⁽²⁾. The organism has been found in high concentrations in warm seawater⁽³⁾. An increased seasonal incidence of wound infections and septicemia in the warm months of April to October has been reported in Florida⁽²⁾. Risk factors for development of this infection include the ingestion of seafood, especially crabs, lobsters, prawns and raw oysters, poor refrigerating and handling of seafood, a history of injury during sea water exposure or a history of employment in oyster shucking, fishing or dockworking^(2,4). Liver disease, alcoholism and diabetes mellitus have been associated with an increased risk of primary septicemia and wound infections. Mortality is increased in patients with septicemia and liver disease⁽²⁾. This is relevant to Singapore where 6% of the population are hepatitis B carriers, of which a significant proportion develop cirrhosis⁽⁵⁾.

Another organism closely related to *Vibrio parahaemolyticus* is *Vibrio vulnificus*. This organism is also a gram negative halophilic organism which is associated with the ingestion of seafood and seawater exposure during injury. It causes the same clinical syndromes as *V. parahaemolyticus*. However, it is associated with a higher mortality of up to 57%^(2,6). This case was initially thought to be due to *V. vulnificus* and was treated as such. Wound infections and primary septicemia caused by this organism classically produce haemorrhagic bullae associated with necrotising fasciitis, cellulitis or pyomyositis⁽⁶⁾.

Treatment of this infection includes early recognition of the organism. This is suspected based on the history of exposure to seafood or seawater at the time of injury. Appropriate antibiotics should be administered without delay for soft tissue infections and septicemia and include doxycycline in combination with a third generation cephalosporin such as ceftazidime, an aminoglycoside or possibly chloramphenicol^(3,7). Surgical debridement of soft tissue infections is indicated early if the disease progression is rapid⁽³⁾.

CONCLUSION

We conclude that necrotising fasciitis caused by *Vibrio parahaemolyticus* requires aggressive therapy with early surgical intervention and appropriate antibiotics, together with prompt supportive care. This organism needs to be recognised early and is relevant to Singapore where the ambient sea water temperature promotes growth of this organism, with sea water exposure and ingestion of seafood which are common. Expedient treatment is essential to reduce morbidity and mortality.

REFERENCES

1. Green RJ, Dafoe DC, Raffin TA. Necrotising fasciitis. *Chest* 1996; 110:219-29.
2. Hlady WG, Klontz KC. The Epidemiology of *Vibrio* Infections in Florida, 1981-1993. *J Infect Dis* 1996; 173: 1176-83.
3. Clemence MA, Guerrant RL. *Vibrio* Infection. In: Schlossberg D, editor. *Infections of Leisure*. New York: Springer-Verlag. 1994:68-90.
4. Barker WH. *Vibrio Parahaemolyticus* Outbreaks in the United States. *Lancet* 1974; 1:551-4.
5. Guan R. Hepatitis B Infection in Singapore. *Gut* 1996; 38 (suppl); S13-S17.
6. Chuang YC, Yuan CY, Liu CY, Lan CK, Huang AHM. *Vibrio Vulnificus* Infection in Taiwan: Report of 28 Cases and Review of Clinical Manifestations and Treatment. *Clin Infect Dis* 1992; 15:271-6.
7. Klontz KC, Lieb S, Schreiber M, Janowski HT, Baldy LM, Gunn RA. Syndromes of *Vibrio Vulnificus* Infections. Clinical and Epidemiological Features in Florida Cases, 1981-1987. *Ann Intern Med* 1988; 109:318-23.